



ZAZIC

Scaling Up Safe Voluntary Medical Male Circumcision

Urethrocutaneous fistula Cases

Dr Vernon Murenje

11 October 2017

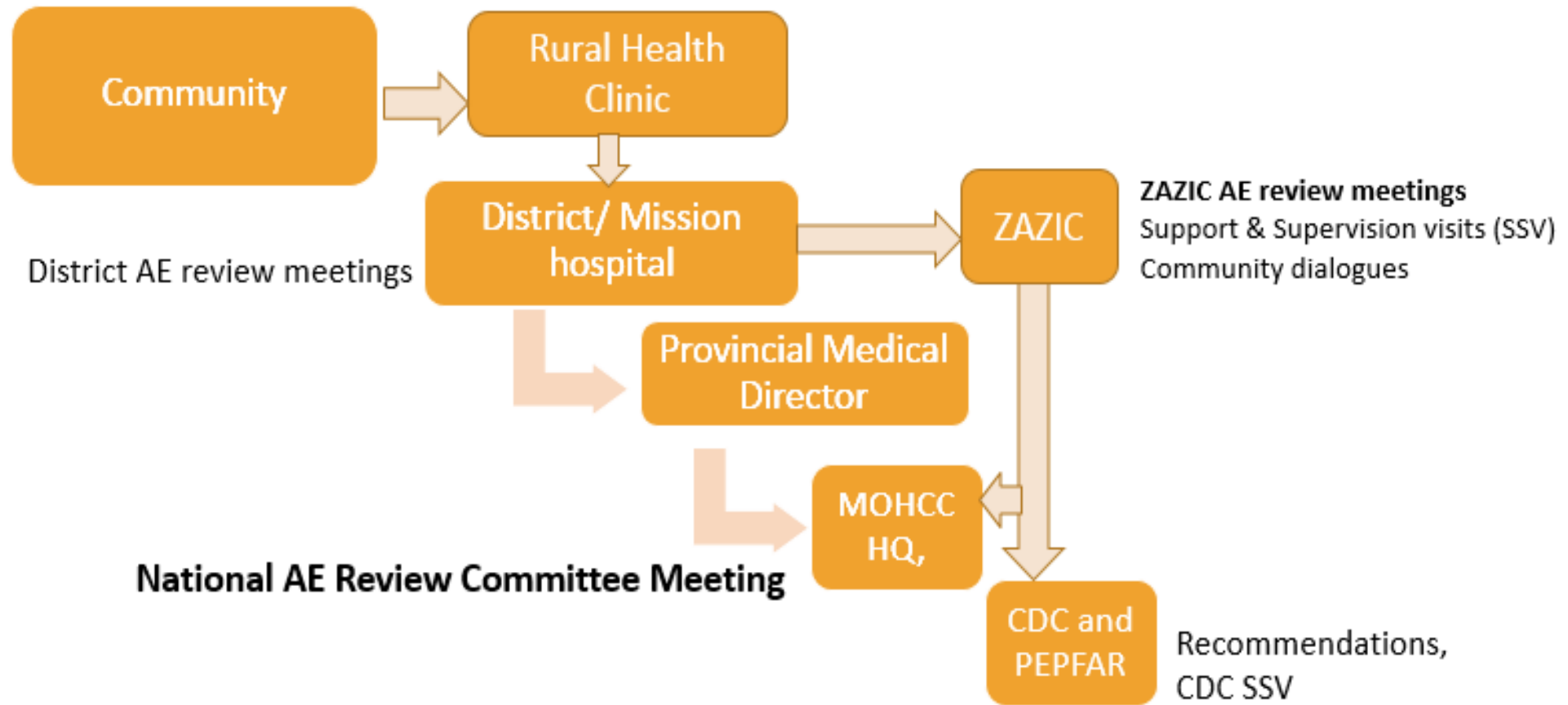
Outline

- ZAZIC consortium background
- AE Surveillance system
- Identifying urethrocutaneous fistulas as a problem
- Fistula case details

Background of ZAZIC consortium

- One of the partners assisting Zimbabwe Ministry of Health & Child Care (MOHCC) with scale up of VMMC
- ZAZIC consortium:
 - I-TECH
 - Zimbabwe Association of Church-Related Hospitals (ZACH)
 - Zimbabwe Community Health Intervention Research (ZiCHIRe)
- Funded by PEPFAR through CDC I-TECH Co-Ag
- 242 776 MCs since 2013 up to end Aug 2017,
- Safe VMMC -quality services, AE identification, management and prevention
- 5 cases of urethrocutaneous fistulas in the program

AE surveillance system



Identifying fistulas as a problem

- Five cases reported through February 2017
- One healed, 4 active with a longstanding case with 5 unsuccessful repairs at a cost of \$18,000
- Managed by government consultants, direct referral
- AE cases discussed at National AE Review Committee meetings
- Meeting held with Urologists & Gen Surgeons-fistulas difficult to manage and prevention key
- PI consulted CDC on options of managing cases and extent of the problem in other programs

Client	Case 1	Case 2	Case 3	Case 4	Case 5
Age (years)	22	16	10	11	12
Procedure	FG	FG	DS	DS	DS
*Provider					
Experience	Dr	Dr	Dr	Dr	Nurse
Date of VMCMC:	12'-08-13	24'-04-14	24-02-2015	21'-09-16	17'-02-17
Days to diagnosis after operation	14 days	10 days	15 days	42 days	18 days
Dates of Repair and Expertise	GMO-Aug & Sep 2014 Urologist 1-Nov 2014 Urologist 1-March 2015 Urologist 2-Aug& Nov 2015 Urologists 1&2-March 2017	Catheterised Urologist 3-May 2015 Urologist 2-October 2016	No surgical repair, iv antibiotics for one week and catheterised for 3 weeks.	Urologist 3- January 2017	Urologist 2 Urologist 2- 5 June 17
Outcome and Current Status	Open. Options are repeat repair by simple closure or to do a skin graft possibly with flap.	Open. Bladder stone removed in March 2017, fistula repair deferred	Healed completely without any disability.	Healed for 5 months before opening	Open

Next steps

- Providing care under expertise of trained urologists
- Joint reviews by two urologists(VMMC consultants) under arrangement
- Considered external consultation, but decided to rely on in-country urologists with high level of expertise and need to anticipate long term care in country
- Strengthen post-operative wound care for young men & surgical technique
- CDC and WHO engaged in broader investigation in response to these reports

-
- Questions

Thank You