

# Prevention and management of fistulae after male circumcision: emerging lessons from the VMMC program

Timothy Hargreave, MS, FRCS Ed, FRCP Ed

Urological Surgeon, Dept. Clinical Sciences, Edinburgh University, Scotland, UK

Co – Chair Technical Advisory Group on Devices and Innovations in Male Circumcision,  
Dept. of HIV, World Health Organization, Geneva. October 11, 2017

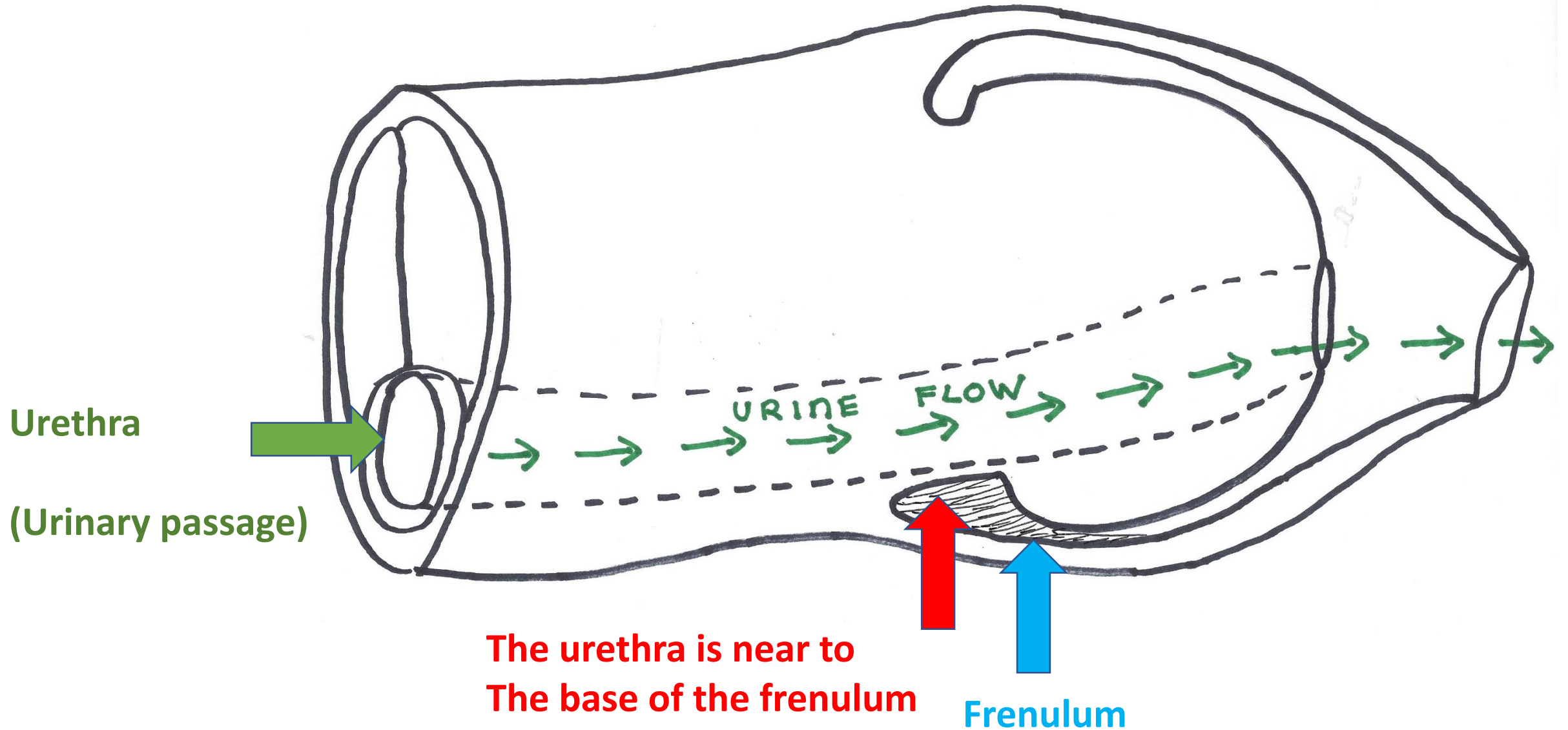
*[Content primarily from forthcoming*

*WHO Informational Note on Fistulas in VMMC]*

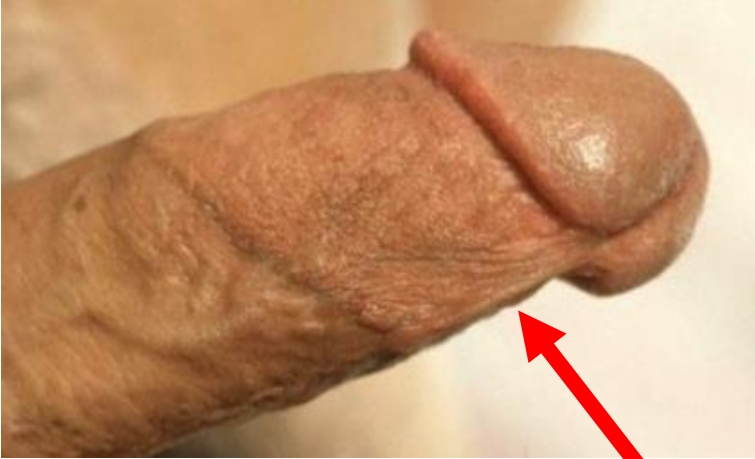# Why fistulas, why now?

- 25+ known cases in PEPFAR programs in past 3 years; likely more unreported.
- It is difficult to make a surgical repair once a fistula has occurred and unless reconstructive surgery is done by an expert this can be a lifelong problem.
  - Many reported cases still being followed:
    - some still undergoing multiple surgical repairs
    - other resolved after multiple procedures
- More information needed to better understand why this is happening. The following slides show possible ways that damage may cause a fistula.

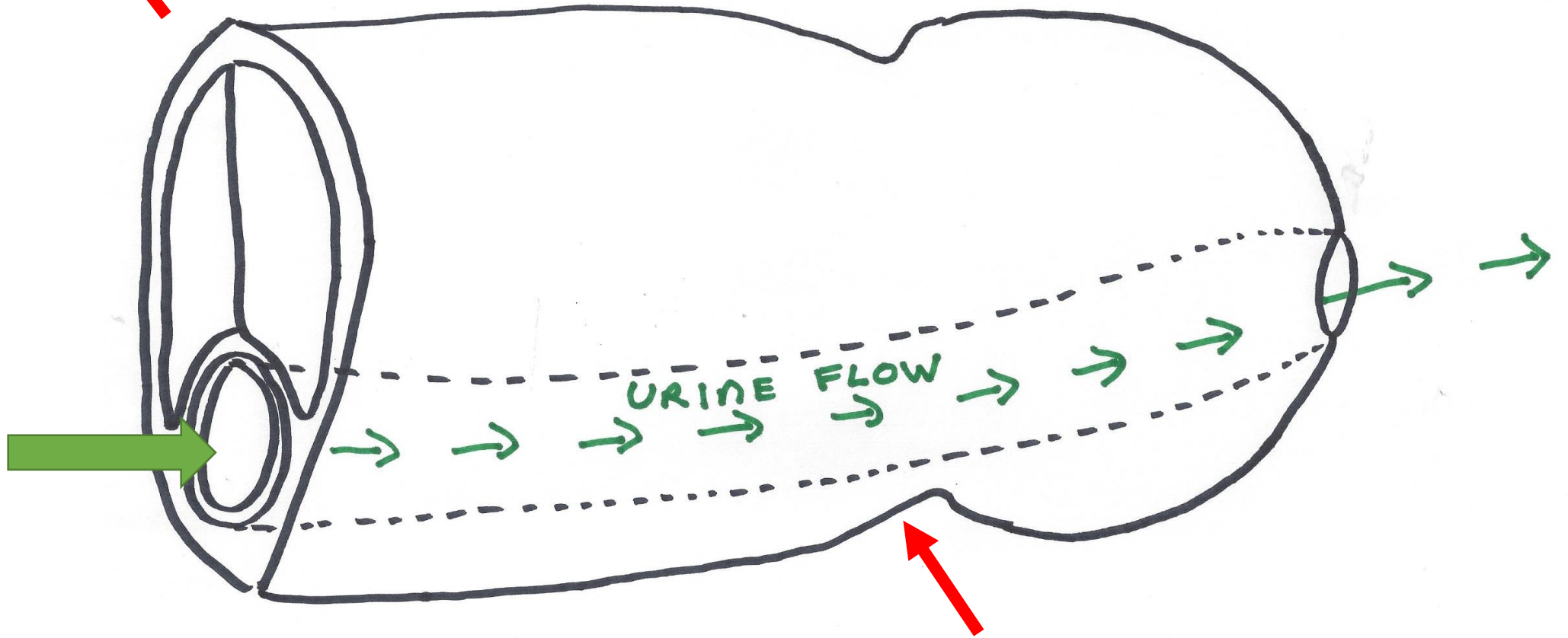
Cross section of uncircumcised penis  
showing the proximity of the urethra to the base of the frenulum

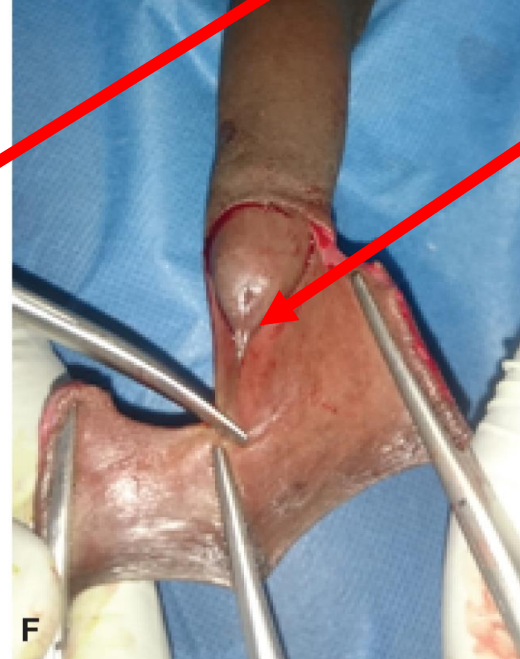
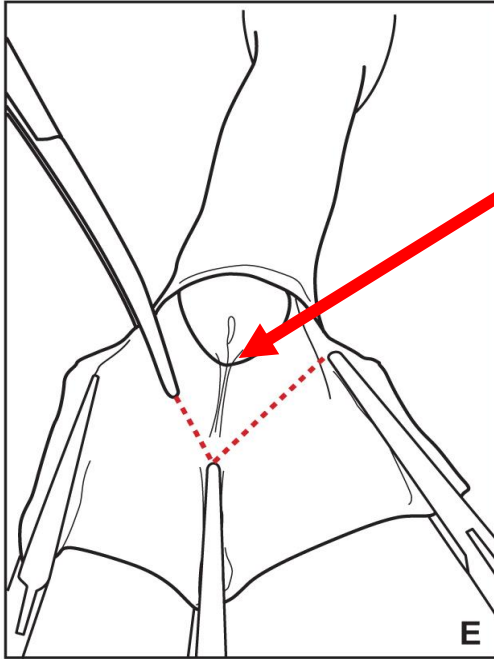
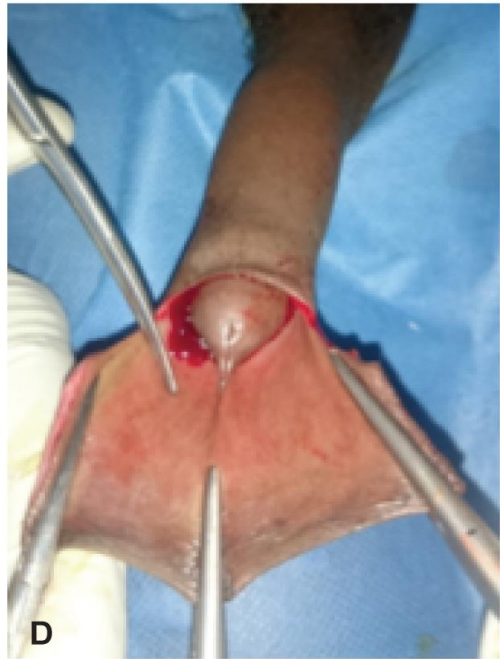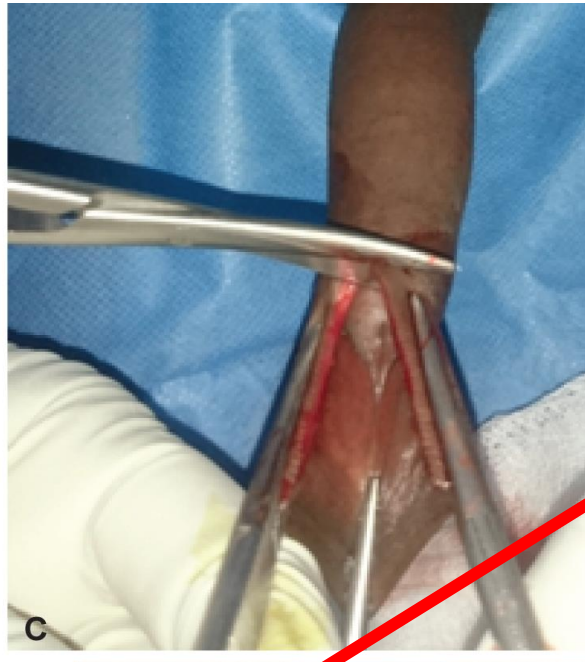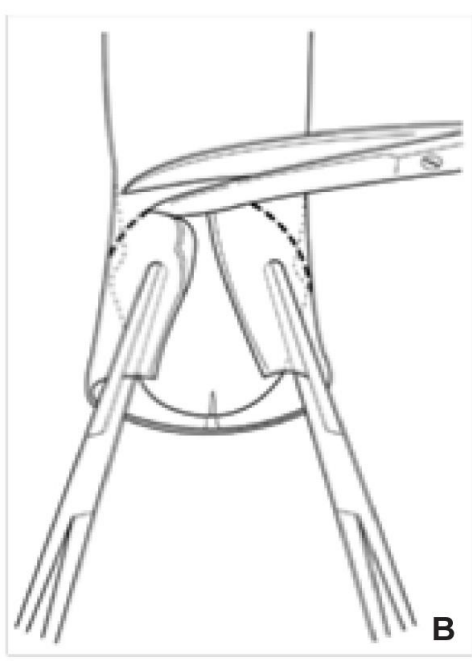


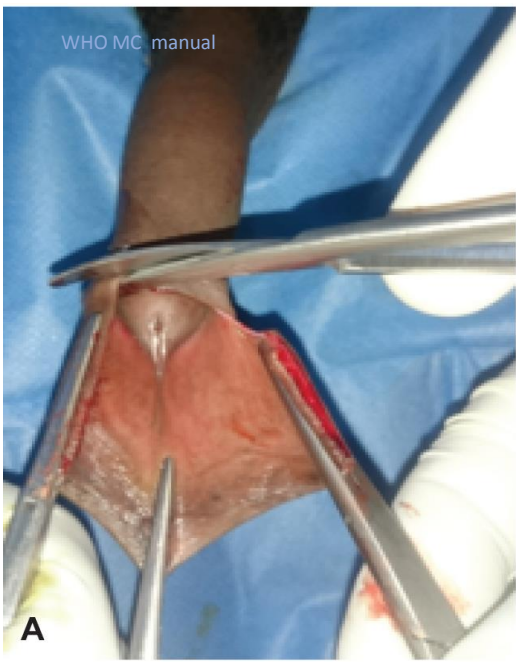Anatomy of the penis post circumcision and foreskin removal to show the relationship of the urethra to the underside (frenular area) of the penis (red arrows)



Urethra



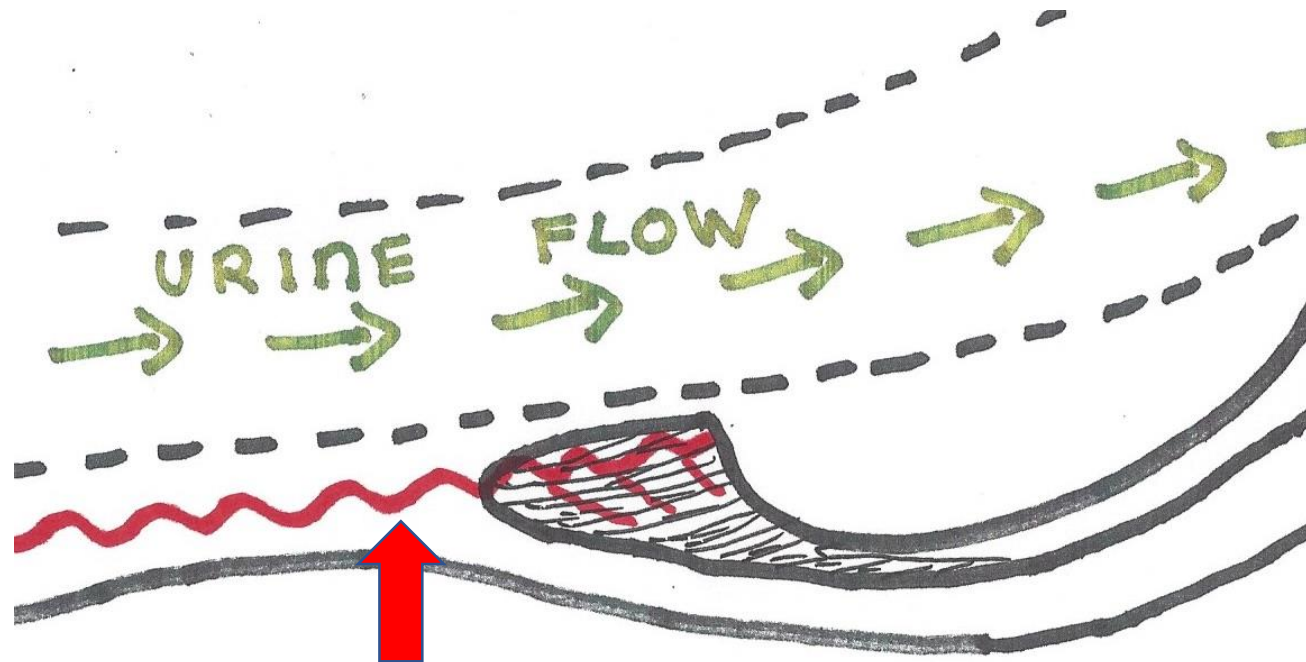
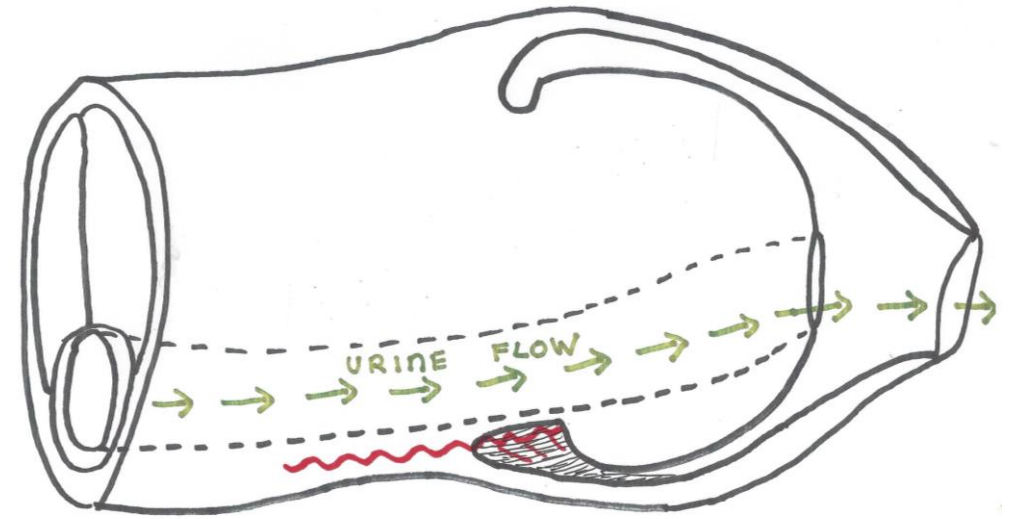


**Cutting too close to the base of the frenulum or cutting into tissues deep to the frenulum can cause bleeding from the frenular artery or a cut into the urethra**

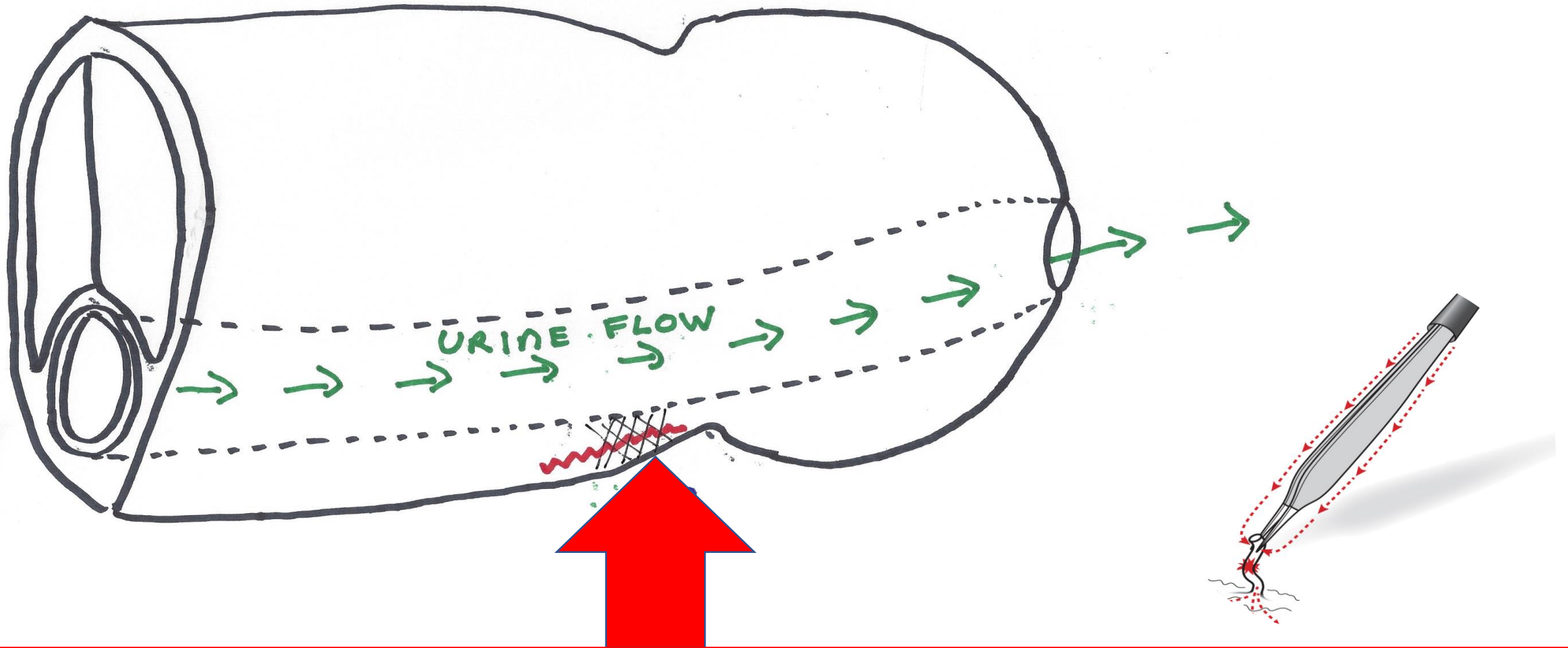
The frenular artery is near the base of the frenulum and bleeding can be difficult to control.

A transfixion stitch can catch the urethral wall if placed too deeply and cause tissue necrosis.

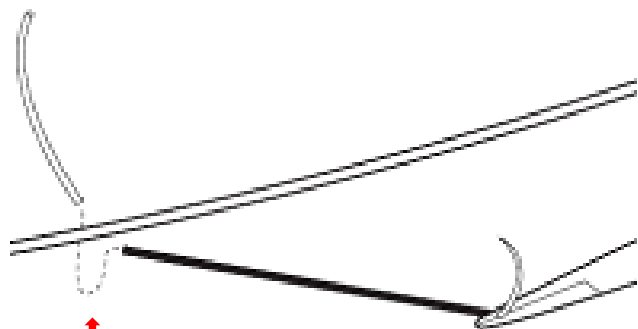
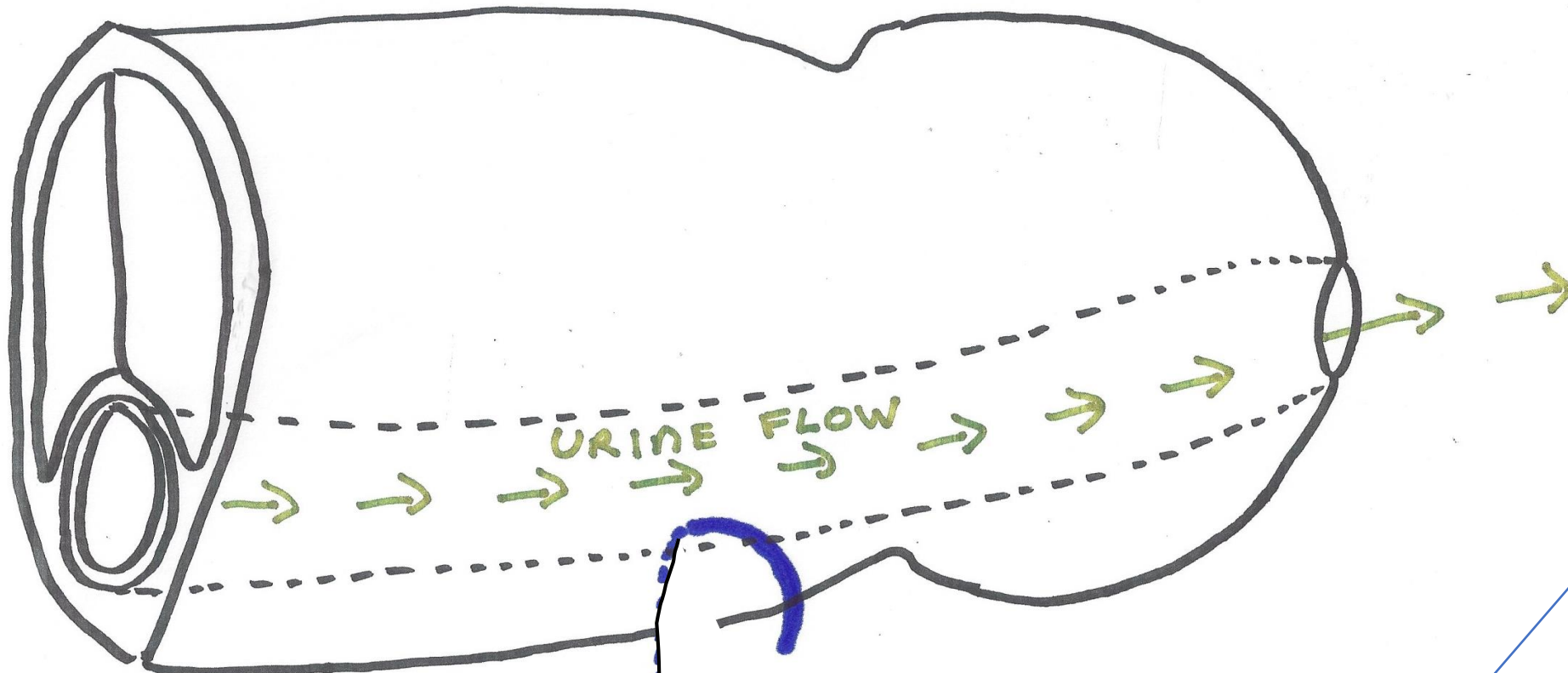
Diathermy can cause a full **thickness** burn



**Frenula Artery**

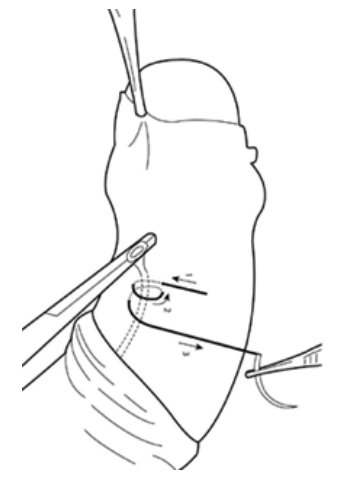


**Use of diathermy near the base of the frenulum risks a full thickness burn through to the urethral wall and development of a fistula. The fistula does not appear immediately but only after the burnt tissues have necrosed ( 2- 6 weeks or longer) after the burn injury.**

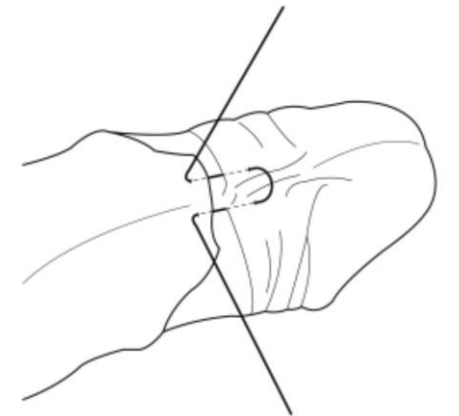


Not too deep!!

Accidentally **placing**  
haemostatic or closing  
**sutures too deeply**  
and transfixing the wall of  
the urethra



Using a suture  
to transfix a blood  
vessel



6 o'clock closing  
mattress suture



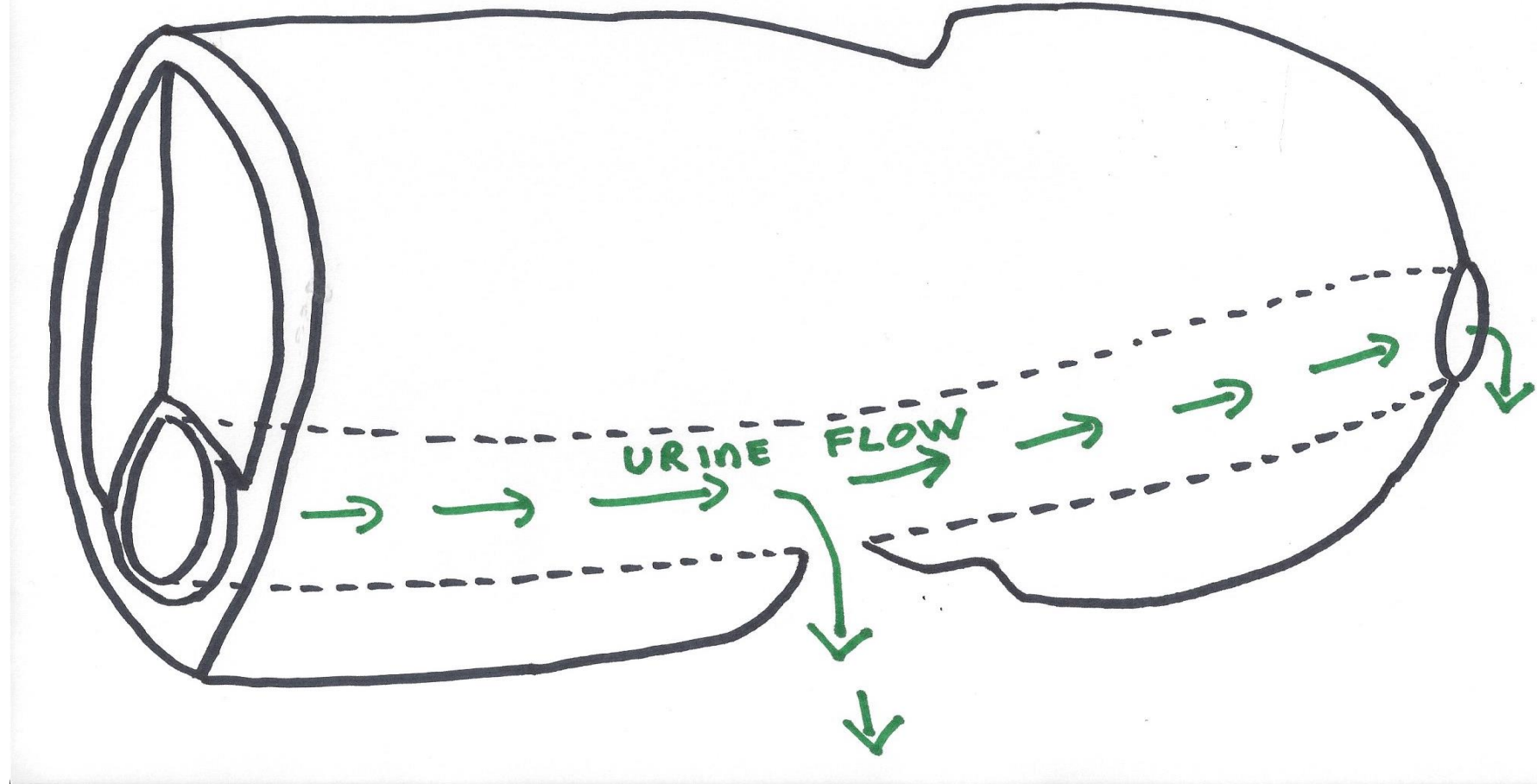
## Infection.

Although infection or delayed wound healing may contribute to fistula formation these factors alone do not normally result in urethral fistula unless there has also been damage to the tissues forming the urethral tube (spongy erectile tissue and urethral muscular and epithelial wall). This is because the erectile tissue surrounding the urethra has a rich blood supply which is independent of the overlying skin and subcutaneous tissue. However if any part of the urethral tube has been damaged by cuts, stitches placed too deeply, or diathermy burns then infection may hasten necrosis of the urethral wall.

## Adhesions.

Normally juvenile penile adhesions separate easily with blunt dissection using a swab or a probe. If there are dense adhesions and it is necessary to use a knife or scissors then there is a risk that accidental cutting into deeper tissues could cause a fistula.

If the fistula is large most or all of the urine comes out through the fistula instead of the urethral meatus at the end of the penis. Sometimes, when there is a very small fistula, there may only be slight dampness and a pinhole fistula can be hard to see (*if the man complains of dampness then there is probably a fistula and he should be referred to an expert*).



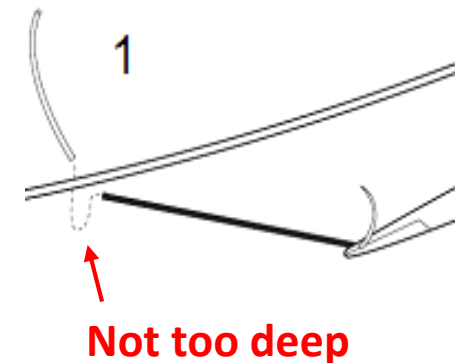
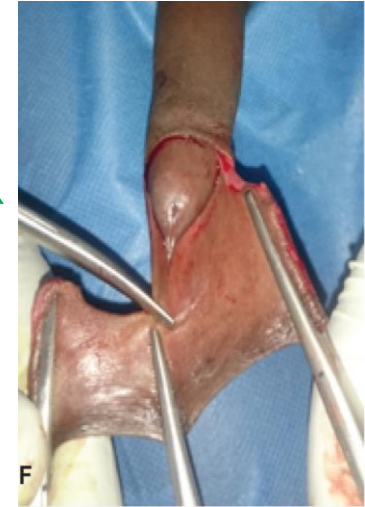
# Why do fistulas form after MC?

- Early fistulas (usually immediate or within 1-3 days): probably due to an accidental cut into the urethra during the procedure when the foreskin is being cut off or perhaps when adhesions are divided using a sharp instrument.
- Later fistulas (1 week or longer): damage to wall of urethra may be due to stitches placed too deeply, diathermy or because cuts have been into the urethral wall. Infection in combination with damage to the urethral wall makes fistula more likely. It can take days or weeks for tissues to necrose and open into a passage between the urethra and the skin surface.
  - Misplaced stitches may happen in a rush to stop frenular bleeding
  - This dead tissue can increase risk for infection, and infection may also increase risk for fistula
- Any fistula – contributing factors
  - Provider fatigue or rush
  - Most cases reported to PEPFAR have been in the 10-14 yr. age group. This may be because the penis is less developed and tissues are thinner between the urethra and the skin.
  - MC method: occurred after dorsal slit or forceps; none yet reported after MC devices

# Preventing fistulas

- Take care when dividing adhesions with a sharp instrument not to cut into deeper tissues
- Great care when cutting foreskin away in frenula area
  - Angle the cut – from inner foreskin to outer edge of frenulum, not from base of frenulum to shaft of penis
- When stopping frenula bleeding
  - avoid diathermy at the frenulum, especially prolonged use
  - use fine suture material if necessary to place sutures
  - carefully locate the bleeding vessel to place the suture correctly and avoid catching deeper layers
- When placing the 6 o'clock horizontal mattress suture, be careful not to catch deeper layers

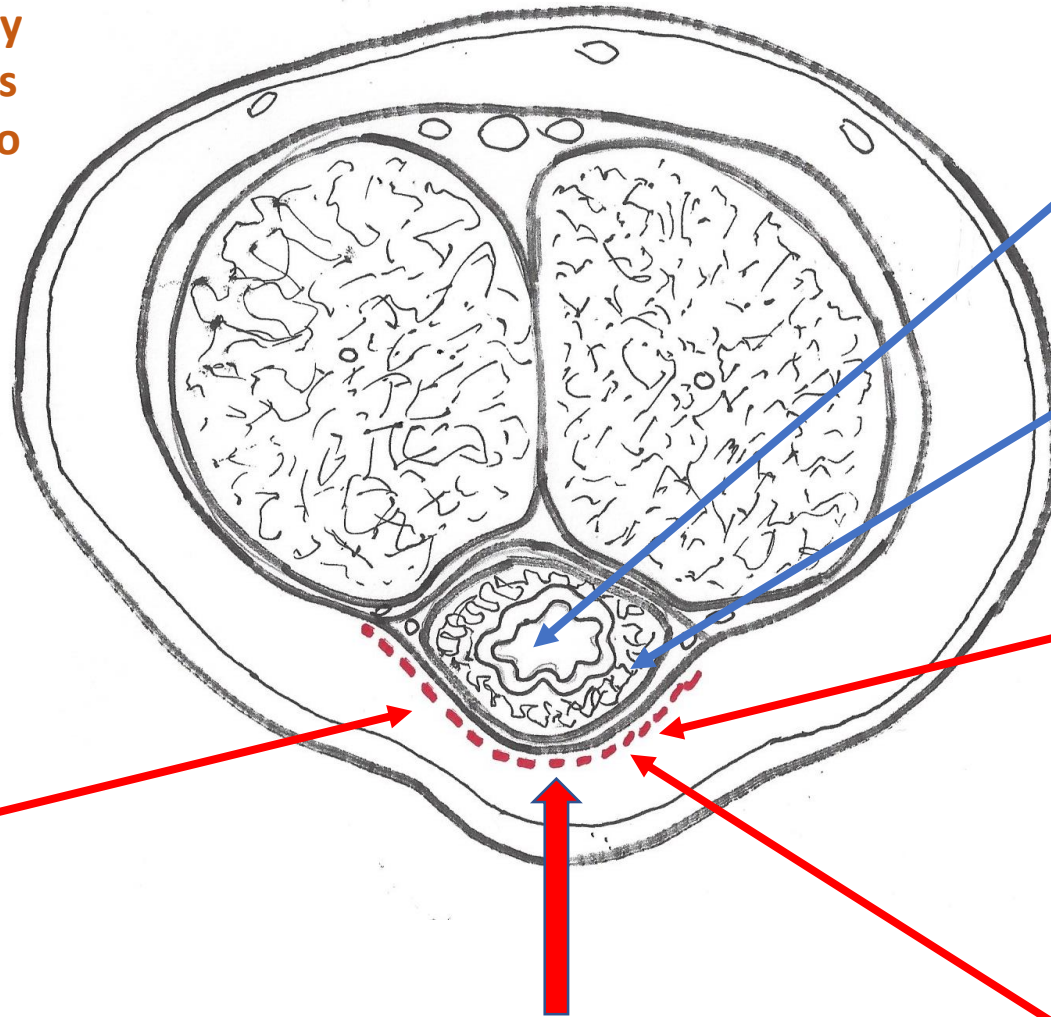
This is the correct angle of cut at the frenulum



**Infection of the skin and subcutaneous tissue is unlikely to cause urethral fistula unless there has also been damage to the urethral wall**

Injury to the urethral tube caused by a sharp instrument

- The final part of cutting away the foreskin in the 6 o'clock position.
- Possible when a sharp instrument is used to divide adhesions.



**Cross section of the penis**

**Urethral lumen**

**Erectile tissue forming part of the wall of the urethral tube.**

Do not use diathermy at base of frenulum



Take care not to catch deep tissues when placing haemostatic or closing stitches.

**Any damage internal to the red dotted line causes damage to the urethral tube and may result in a fistula**

# When fistulas happen

- Always refer promptly to a regional urologist/specialist; non-specialist providers should never attempt repair
  - inexpert attempts can lead to need for multiple surgical operations and a lifelong problem with urinary leakage through a fistula and often with the additional problem of urethral stricture.
- Urologist may choose to intervene by:-
  - Surgical repair
  - Conservative management: place urinary catheter to protect the fistula from urine and await natural healing. This may work for a fistula diagnosed immediately or very soon (1-3 days) after surgery but does not work when there is an established fistula because the epithelial surface of the tract prevents healing.

# Reporting

- Report to the relevant national programme/safety monitoring committee
  - For PEPFAR, report through adverse event reporting channel
  - For WHO: report to WHO Country officer along with report to national programme
- To better understand and mitigate these adverse events, further information is required. Please can you help us to do this.
- PEPFAR and WHO are jointly developing a reporting form
  - Client age, MC technique, anatomic abnormalities (adhesions, tight foreskin or frenulum), surgical complications (frenular bleeding, frenuloplasty), use of diathermy, timing of fistula diagnosis, other postoperative complications, provider experience and opinion on contributing factors
  - Photographs where possible (must obtain consent)
  - Submit to WHO HIV Country Officer and PEPFAR.....

**Urethral Fistula Report form**

*Based on a small number of urethral fistulas following male circumcision, this report form has been developed to encourage reporting of useful information. Urinary fistula is a condition where a hole develops from the urinary passage to the outside so that the urine no longer comes out from the tip of the penis but through a hole in the skin somewhere else on the penis. To prevent this problem, understand the reason and improve practice, more information is needed when an event occurs.*

*It is helpful if you can give a clinic ID number so that if we have any further questions we can ask. If we have no further questions then we will remove the clinic ID number from this record. If you have any photographs of the fistula then it would be very helpful if we can have a copy of the photograph, with a note of the date on which it was taken.*

Clinic ID number .....

**Client details**

Age of client at time of circumcision: .....

Date of circumcision: .....

Date client or parents first noticed that urine was not coming out the proper way: .....

Date when the client came to the clinic with this problem: .....

If you can, please circle the situation that was more like that of your client:

- HIS PENIS WAS MORE LIKE THAT OF A FULLY GROWN ADULT MAN
- HIS PENIS WAS MORE LIKE THAT OF A YOUNGER IMMATURE BOY

Were any anatomical problems noted before the operation? If yes, please copy out the exact wording recorded in the case report form.

Version: 24 July 2017

# Discussion

- Audience questions
- How often do you hear about fistula cases in your country or program?
- What attributes observed in fistula cases do you suspect are contributing factors?
- Have you observed 'clusters' of fistula cases in areas of your country? What do you think causes these?
- What do you think might help decrease numbers of cases? (focused refresher trainings, hemostasis technique modifications, other resources?)
- [other information you would like to collect?]